ACMISST発表

2013/3/29-3/30

愛知県犬山市名鉄犬山ホテルにおいて
開催された国際学会において杉田医師は
頚椎の低侵襲的椎弓形成術について発表しました。

Certificate

This is to certify that

Kyoichi Sugita

has participated in
The 2nd Asian Congress of Minimally Invasive
Spine Surgery & Techniques
combined with the 6th MISS Summit Forum

March 29-30, 2013

Fujio Ito

Fujio Ito, M.D.,Ph.D.
President

Inuyama City, Aichi, Japan March 29-30 2013
ACMISST 2013 JAPAN
The 2nd Asian Congress of Minimally Invasive Spine Surgery & Techniques

MISS SUMMIT FORUM

The 2nd Asian Congress of Minimally Invasive Spine Surgery & Techniques

combined with The 6th MISS Summit Forum

Program & Abstracts

Dates March 29-30, 2013

Venue Meitetsu Inuyama Hotel,
Inuyama City, Aichi, Japan

President Fujio Ito, MD, PhD

Web : http://acmisst.com/
E-mail : acmisst@itoortho.or.jp

Inuyama City, Aichi, Japan
March 29-30 2013
ACMISST 2013 JAPAN
The 2nd Asian Congress of Minimally Invasive Spine Surgery & Techniques

MISS SUMMIT FORUM

Program

Inuyama City,
Aichi, Japan
March 29-30
2013

ACMISST
2013 JAPAN

The 2nd Asian Congress of Minimally
Invasive Spine Surgery & Techniques

DAY-2 March 30. Sat



B2-2-7

Kyoichi Sugita, M.D., Ph.D.
Department of Neurological Surgery, Azuhata Hospital, Ibaraki, Japan

History & Education

Degrees

1980 Tohoku University School of Medicine, MD
1988 Tohoku University School of Medicine, PhD

Residency

1982-1988 Department of Neurological Surgery, Tohoku University

Faculty

1988 Department of Neurological Surgery, Mito National Hospital, Ibaraki, Japan
1997 Chief, Department of Neurological Surgery, Mito National Hospital
2007 Director of the Emergency Room, Mito Medical Center, Ibaraki, Japan
2012 Chief, Department of Neurological Surgery, Azuhata Hospital, Ibaraki, Japan

Research and Clinical Interests

Brain ischemia
Biology of the artificial bone
Metabolism of the central nervous system
Cerebral vascular disease
Acute medicine
Spinal cord injury
Neurological surgery
Spinal surgery

Evidence-based minimally invasive cervical laminoplasty

Kyoichi Sugita, M.D., Ph.D.
Department of Neurological Surgery, Azuhata Hospital, Ibaraki, Japan

Recently the increase of the old people in Japan requires much more surgical treatment of the spine disease. In this paper reported are basic data of the size of the spinal canal of people of today and the surgical cases, the surgical method and result of the cervical laminoplasty with midline splitting of the spinous process. At first the size of the cervical spinal canal differs in each cervical spine; this is supported by the data of 200 trauma patients and many patients who had surgical treatments. Preopereative evaluation of the precise transverse diameter of the cervical spinal canal produces safe and good decompression of the spinal cord by laminoplasty. The surgical result and prognosis is favorable even in the high age patients. The risk of the laminoplasty was very low including lamina destruction, infection, postoperative epidural hematoma, decompression myelopathy or radiculopathy and infection. Follow-up data revealed good outcome until the 70s-age group and half of the patients over 80 had good recovery. Economically good surgical result decreases the medical cost of the elderly people maintaining the healthy state.

B2-1-10 10:33-10:43 Symptoms and Clinical Examinations for Assessment of Lumbar Spinal Instability
Yuichi Kasai
(Department of Spinal surgery and medical engineering, Mie University Graduate School of Medicine)

12:00-13:00 **Luncheon Seminar III**

Moderator: Dr. Motohide Shibayama

New approach and changes in the microhemodynamics of nerve root retraction in patients with lumbar spinal canal stenosis in minimally invasive surgery
Akira Dezawa
(Department of Orthopaedic Surgery, School of Medicine, University of Teikyo, Mizonokuchi Hospital, Japan)

Support company : Ono Pharmaceutical Co., Ltd.

DAY-2
Room-B

13:15-14:30 **B2-2**
[Cervical]

Moderator: Dr. Masakazu Takayasu / Dr. Kazutoshi Hida

B2-2-1 13:15-13:22 Fales localizing sign of cervical cord compression presented with mid truncal pain
Hyung Suk Kim, Soo-Yong Park, Yoo-Hyun Cha
(Seoul Gimpo Airport Wooridul Spine Hospital)

B2-2-2 13:22-13:29 Effective cervical decompression by posterior cervical foraminotomy without discectomy
Min-Soo KANG
(Daegu Wooridul Spine Hospital)

B2-2-3 13:29-13:36 Transcorporeal tunnel approach for unilateral cervical radiculopathy: a 2-year follow-up review and results
Gun Choi
(Department of Neurosurgery, Seoul Wooridul Hospital, Seoul, South Korea)

B2-2-4 13:36-13:43 Minimally invasive key hole foraminoplasty using percutaneous spinal endoscope for cervical spondylotic radiculopathy
Kitagawa Y, Sairyo K, Dezawa A.
(Department of Orthopaedic Surgery, School of Medicine, University of Teikyo, Mizonokuchi Hospital, Takatsu-ku, Kawasaki City, Japan.)

B2-2-5 13:43-13:50 Minimal invasive hybrid cervical surgery to avoid spinal fusion
Hyon-Su Chong, Gun Choi, Kang-Seok Moon
(Seoul Gimpo Airport Wooridul Spine Hospital)

B2-2-6 13:50-14:00 Transvertebral key-hole foraminotmy for cervical radiculopathy
Masakazu Takayasu, Aichi Niwa, Mikinobu Takeuchi, Masahiro Yoko, Muneyoshi Yasuda
(Dept. of Neurological Surgery, Aichi Medical University)

B2-2-7 14:00-14:10 Evidence-based minimally invasive cervical laminoplasty
Kyoichi Sugita
(Department of Neurological Surgery, Azuhata Hospital, Ibaraki, Japan)

The 2nd Asian Congress of Minimally Invasive Spine Surgery & Techniques

combined with the 6th MISS Summit Forum

Name: Kyouichi Sugita

Affiliation: Department of Neurosurgery, Azuhata Hospital

Country: Japan

Inuyama City, Aichi, Japan March 29-30 2013

ACMISST 2013 JAPAN

The 2nd Asian Congress of Minimally Invasive Spine Surgery & Techniques

MISS SUMMIT FORUM

Please Come to your Lecture room
15min before your Lecture

March 30,Sat
B2-2-7:(14:00-14:10)
Room-B

彩雲

Inuyama City,
Aichi, Japan
March 29-30
2013

ACMISST
2013 JAPAN

The 2nd Asian Congress of Minimally
Invasive Spine Surgery & Techniques


data of the si
today and the
method and
with midline
This is a mini
small damag

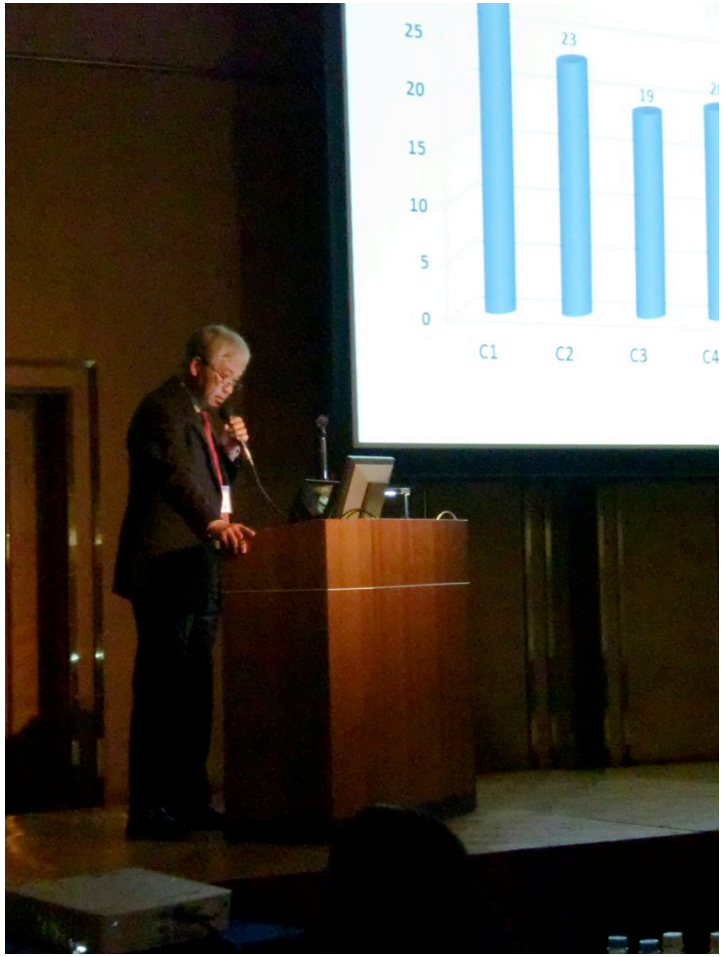
25
20
15
10
5
0
23
19
C1
C2
C3

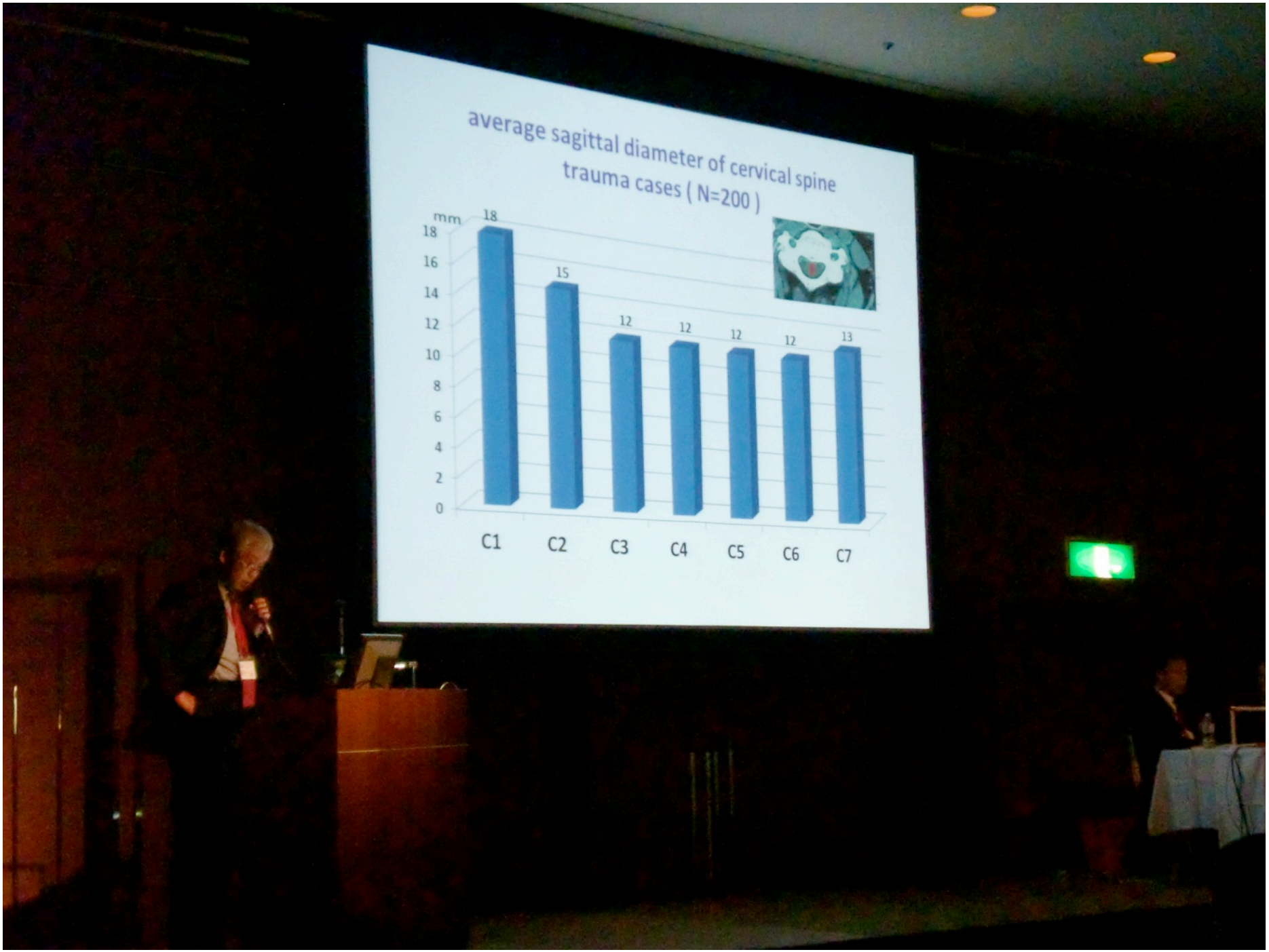
average sagittal diameter of cervical spine trauma cases (N=200)
mm
18
16
14
12
10
8
6
4
2
0
18
15
12
12
12
12
13
C1
C2
C3
C4
C5
C6
C7